

Sponsored by



www.edsdental.com

THE JOURNAL OF THE AMERICAN DENTAL ASSOCIATION



Lingual nerve damage due to inferior alveolar nerve blocks: A possible explanation

M. ANTHONY POGREL, B.L. SCHMIDT, V. SAMBAJON and R.C.K. JORDAN
J Am Dent Assoc 2003;134:195-199

The following resources related to this article are available online at jada.ada.org (this information is current as of February 23, 2011):

Updated information and services including high-resolution figures, can be found in the online version of this article at:

<http://jada.ada.org/cgi/content/full/134/2/195>

This article appears in the following **subject collections**:

Endodontics <http://jada.ada.org/cgi/collection/endodontics>

Information about obtaining **reprints** of this article or about permission to reproduce this article in whole or in part can be found at:

<http://www.ada.org/prof/resources/pubs/jada/permissions.asp>

Downloaded from jada.ada.org on February 23, 2011

Lingual nerve damage due to inferior alveolar nerve blocks

A possible explanation

M. ANTHONY POGREL, D.D.S., M.D.; B.L. SCHMIDT, D.D.S., M.D., Ph.D.; V. SAMBAJON, D.D.S., M.D.; R.C.K. JORDAN, D.D.S., Ph.D.

It is known that, on rare occasions, an inferior alveolar nerve block can cause permanent paresthesia, anesthesia or dysesthesia of both the inferior alveolar and lingual nerves. There are only a small number of studies of this phenomenon in the literature,¹⁻¹⁰ which suggest an incidence ranging from one in 26,000 inferior alveolar nerve blocks² to one in 800,000⁵

inferior alveolar nerve blocks. Most studies show that lingual nerves rather than inferior alveolar nerves are predominantly affected, and the lingual nerve may be affected in up to 70 percent of cases.^{2,5} Another observation that has been made is that when there is nerve damage after an inferior alveolar nerve block, it generally is the entire anatomical distribution of the nerve that is affected rather than a smaller portion of it.²

The University of California, San Francisco, has acquired a reputation as a tertiary referral center for patients with injuries to the inferior alveolar and lingual nerves. It has been our experience in the evaluation of more than 100 patients with nerve damage that only could have resulted from inferior alveolar nerve blocks that the pattern of injury always affects the full distribution of the nerve and does not appear to indicate damage to just one or two fascicles. This is in contrast to patients seen with nerve damage as a result of dentoalveolar trauma (mainly removal of third molars), where a fascic-

When an inferior alveolar nerve block causes permanent nerve impairment, the lingual nerve is affected about 70 percent of the time, possibly because of its fascicular pattern.


Background. An explanation for the predominance of injuries to lingual nerves over those to inferior alveolar nerves as a result of inferior alveolar nerve blocks may be due to the nerves' fascicular pattern. A unifascicular nerve may be injured more easily than a multifascicular nerve.

Methods. The authors unilaterally dissected lingual and inferior alveolar nerves from 12 cadavers. They cut the specimens 2 millimeters above the lingula for both the lingual nerve and inferior alveolar nerve and opposite the site of the middle of the third molar for the lingual nerve, and they counted the number of fascicles at each site.

Results. For the lingual nerve at the lingula, the mean number of fascicles was three (range, one to eight). Four of the 12 nerves (33 percent) were unifascicular at this point. Opposite the third molar, the lingual nerve had a mean of 20 fascicles (range, six to 39). In every case, there were more fascicles in the third molar region than above the lingula in the same nerve. At the lingula, the inferior alveolar nerve had a mean of 7.2 fascicles (range, three to 14).

Conclusion. This study may explain the observation that when an inferior alveolar nerve block causes permanent nerve impairment, the lingual nerve is affected about 70 percent of the time and the inferior alveolar nerve is affected only 30 percent of the time. In 33 percent of cases, the lingual nerve had only one fascicle at the lingula; a unifascicular nerve may be injured more easily than a multifascicular one.

Clinical Implications. There is no known way to avoid the remote possibility of nerve damage resulting from an inferior alveolar nerve block. The lingual nerve may be predominantly affected because of its fascicular pattern.



ular pattern of damage is seen not infrequently. Although it is likely that we are not seeing every patient with nerve involvement in northern California, at the same time there does appear to be a genuine difference in the distribution pattern of nerve injury as a result of local anesthetic injection vs. nerve injury as a result of local trauma. This does suggest that the whole nerve, not just one fascicle, is affected in some way.

The mechanism of nerve damage is unclear, but theories have included direct needle trauma, hemorrhage inside the epineurium and a neurotoxic effect from the local anesthetic itself.^{2,5} Observation of clinical cases, however, does not fully support any of these theories, since some of the facts fit some of the theories and not others.^{1,2}

In terms of the observed signs and symptoms of patients with permanent injury to the inferior alveolar or lingual nerves as a result of local anesthetic injection, certain inconsistencies arise that make the etiology difficult to ascertain. It has been shown that only just more than 50 percent of a group of such patients were aware of an electric shock or any abnormal discomfort associated with the injection.² Therefore, it can be assumed that in almost 50 percent of cases there was no obvious contact between the needle and the nerve, which would tend to rule out direct trauma from the needle in these cases. Also, there appear to be other differences between permanent nerve injuries resulting from an inferior alveolar nerve block and those resulting from local trauma. Among these differences is the fact that dysesthesia appears to occur much more frequently with nerve damage associated with inferior alveolar nerve block, which may indicate a physicochemical phenomenon associated with the chemical constituents of the local anesthetic. Similarly, the altered sensation sometimes spreads to adjacent nerve branches, which also suggests a physicochemical injury that possibly causes some demyelination.²

We carried out a study to determine whether the fascicular pattern of the inferior alveolar and lingual nerves above the lingula, which where an inferior alveolar nerve block injection typically is given, could have any bearing on the relative incidence of involvement of each nerve.

MATERIALS AND METHODS

We dissected the lingual and inferior alveolar nerves unilaterally from 12 cadavers. We dissected out the lingual nerve from approximately 5

millimeters above the lingula down to the lower second molar region. The inferior alveolar nerve was dissected out from 5 mm above the lingula to where the nerve entered the inferior alveolar canal just below the lingula. We cut and embedded the specimens 2 mm above the lingula (where a nerve block might be injected) for both the lingual nerve and inferior alveolar nerve and opposite the site of the middle of the third molar for the lingual nerve. We cut 5-micrometer sections and stained them with hematoxylin and eosin. Sections were initially screened to ensure cross-sectional orientation. We reoriented and recut cases sectioned tangentially. The number of individual fascicles for each nerve was scored by an experienced pathologist (R.C.K.J.) using $\times 40$ magnification with confirmation at $\times 200$ magnification for smaller bundles. For statistical analysis, results for each nerve type were averaged. Since we assumed the data to be sampled from a Gaussian distribution, we used parametric analysis using a paired Student *t* test to compare means. A *P* value less than .05 was considered significant.

RESULTS

The results of the fascicle count at each point are shown in the table (page 197).

For the lingual nerve sectioned just above the lingula, the mean number of fascicles was three (range, one to 8). Four of the 12 nerves (33 percent) were unifascicular at this point. Opposite the third molar, the lingual nerve had a mean of 20 fascicles (range, seven to 39). In every case, there were more fascicles in the third molar region than above the lingula in the same lingual nerve. This must mean that the fascicles divide at some point between the lingula and the third molar region. Two millimeters above the lingula the inferior alveolar nerve had a mean number of fascicles of 7.2 (range, three to 14). This means that no inferior alveolar nerve was unifascicular at the lingula, and the smallest number of fascicles observed was three. In every case, the lingual nerve had the same number of fascicles as, or fewer fascicles than, the inferior alveolar nerve at the lingula. The difference in the number of fascicles at each site for each nerve was statistically significant ($P < .001$). Examples of representative nerves are shown in the figure.

DISCUSSION

All studies of nerve damage resulting from inferior alveolar nerve blocks have shown a predomi-

TABLE

FASCICULAR PATTERN OF ALL LINGUAL NERVES AND INFERIOR ALVEOLAR NERVE AT THE LINGULA.

NERVE	NUMBER OF FASCICLES	
	Lingual Nerve at Lingula	Inferior Alveolar Nerve at Lingula
1	1	3
2	3	3
3	1	6
4	8	14
5	4	7
6	3	14
7	3	5
8	1	10
9	3	8
10	5	4
11	1	6
12	3	6
Mean	3.0	7.2
Standard Deviation	± 2.0	± 3.8

nance of lingual nerve involvement over inferior alveolar nerve involvement, and it appears that the lingual nerve may be involved up to 70 percent of the time.² There seems no obvious reason for this, since if needle trauma or intraneural hematoma were the cause of the problem, one would expect the distribution to be equal. If the cause of the problem was a neurotoxic effect from the local anesthetic itself, one might expect this to be more frequent in the inferior alveolar nerve than the lingual nerve, since the vast majority of the local anesthetic is deposited in close relationship to the inferior alveolar nerve rather than to the lingual nerve. Also, it has been observed that when permanent nerve involvement does result from an inferior alveolar nerve block, it normally involves the whole distribution of the nerve rather than a patchy distribution that might occur if only one or two fascicles were involved.²

Our study may give at least a partial explanation for these findings. If a nerve were unifascicular at the point of injection, then any injury at this point automatically would affect the whole nerve. Also, if the nerve had only one fascicle,

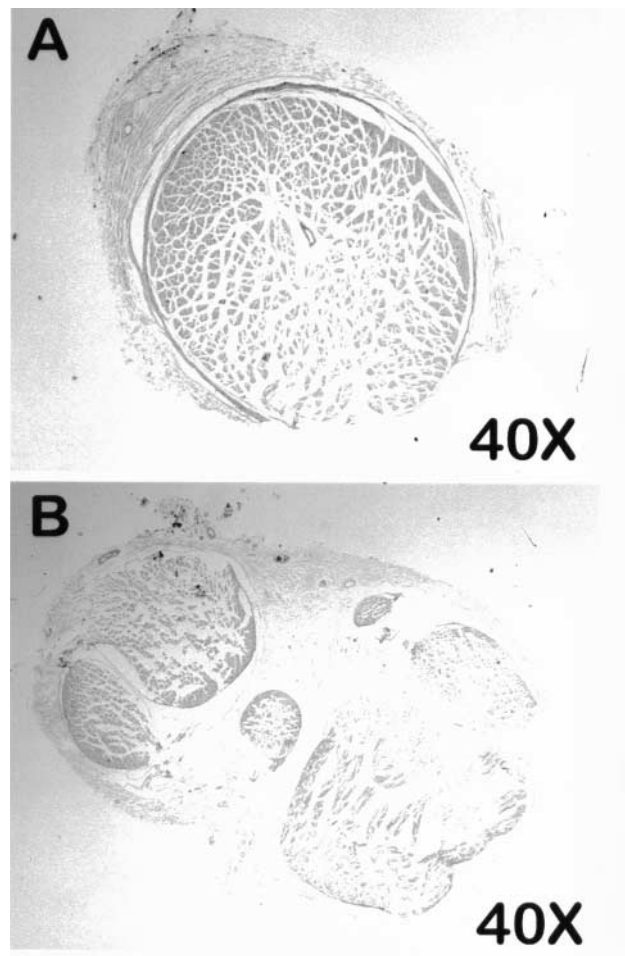


Figure. A composite figure of the lingual and inferior alveolar nerves from the same side of the same cadaver. The case is nerve number 3 in the table (hematoxylin and eosin stain X40). A. Monofascicular lingual nerve at lingula. B. Multifascicular (six fascicles) inferior alveolar nerve at lingula.

there would be no opportunity for other undamaged fascicles to compensate and minimize any possible involvement. This study shows that in about 33 percent of the cases, the lingual nerve may in fact be unifascicular at the point just above the lingula in which an inferior alveolar nerve block might be expected to be given in the vast majority of cases. For the inferior alveolar nerve, the smallest number of fascicles that we saw was three and the mean was 7.2 at the point of deposition of an inferior alveolar nerve block. Therefore, even if one or more fascicles were to be involved, one would expect the overall effect to be much less noticeable or apparent to the patient. One also might expect a better recovery, since there were a number of uninvolved fascicles to give compensatory innervation.

Thus, one can postulate that one of the factors that may influence permanent nerve involvement from an inferior alveolar nerve block might be the needle's coming into contact with a unifascicular nerve, where needle trauma, intra-neural hematoma or a neurotoxic effect from the local anesthetic might be expected to have a more profound and long-lasting result. Since only the lingual nerve has been shown to be unifascicular—and this may occur in about 33 percent of the cases—this would provide an explanation as to why the lingual nerve may be affected to a greater extent than the inferior alveolar nerve. Although it has been noted previously that possibly about 70 percent of permanent nerve injuries caused by an inferior alveolar nerve block occur in the lingual nerve and only about 30 percent in the inferior alveolar nerve, there appears to be no documentation in the literature as to possible explanations for this. This article, therefore, appears to be the first one in the literature to give a possible reason (the fascicular pattern of the nerve in the area where there might be injury).

Conceptually, one could envisage other possible reasons why the incidence should be different, but none of them has been verified. Among other differences is the fact that the nerves are in different locations, though they are approximately the same size. It could be that the lingual nerve is more likely to be injured because of its position. It is certainly true that the lingual nerve, by being exposed below the mandibular foramen, may be more likely to be damaged by a needle, but it also has been shown that the vast majority of cases of needle contact with the nerve do not result in any long-term injury.¹¹

Recommended techniques, including careful aspiration and slow injection, also may help to minimize permanent nerve injury from an inferior alveolar nerve block.¹²

Stopping the injecting and repositioning the needle if the patient feels an "electric shock" also



Dr. Pogrel is a professor and the chairman, Department of Oral and Maxillofacial Surgery, University of California, San Francisco, Box 0440, 521 Parnassus Ave., San Francisco, Calif. 94143-0440, e-mail "map@itsa.ucsf.edu". Address reprint requests to Dr. Pogrel.



Dr. Schmidt is an assistant professor of oral and maxillofacial surgery, Department of Oral and Maxillofacial Surgery, University of California, San Francisco.



Dr. Sambajon is an assistant professor of clinical oral and maxillofacial surgery, Department of Oral and Maxillofacial Surgery, University of California, San Francisco.



Dr. Jordan is an associate professor, Division of Oral Pathology, Department of Stomatology, University of California, San Francisco.

One of the factors that may influence permanent nerve involvement from an inferior alveolar nerve block might be the needle's coming into contact with a unifascicular nerve.

is recommended to minimize the incidence of permanent nerve damage.¹³

CONCLUSIONS

To date, there has been no explanation of the noted phenomenon that on the rare occasion that an inferior alveolar nerve block causes nerve damage, the lingual nerve is affected 70 percent of the time and the inferior alveolar nerve only 30 percent of the time. Our study demonstrates that there is a difference in the fascicular pattern of these two nerves just above the lingula where an inferior alveolar nerve block is normally deposited. At this site, the lingual nerve is unifascicular in one-third of these cases, and a unifascicular nerve may be injured more easily and permanently than a multifascicular nerve, which may have greater powers of recovery.

Clinically, at present, there is no known way to avoid with certainty the possibility of nerve damage resulting from an inferior alveolar nerve block, and it does appear to be a rare but unavoidable risk of the procedure. This study, however, may present an explanation for the predominance of involvement of the lingual nerve over the inferior alveolar nerve. ■

1. Pogrel MA, Schmidt BL. Trigeminal nerve chemical neurotrauma from injectable materials. *Oral Maxillofac Surg Clin Am* 2001;13:247-53.
2. Pogrel MA, Thamby S. Permanent nerve involvement resulting from inferior alveolar nerve block. *JADA* 2000;131:901-7.
3. Haas DA. Localized complications from local anesthesia. *J Calif Dent Assoc* 1998;26(9):677-82.
4. Haas DA, Lennon D. A review of local anesthetic-induced paresthesia in Ontario in 1994 (abstract 1384). *J Dent Res* 1996;75:247.
5. Haas DA, Lennon D. A twenty-one-year retrospective study of reports of paresthesia following local anesthetic administration. *J Can Dent Assoc* 1995;61:329-30.
6. Pogrel MA, Bryan J, Regezi J. Nerve damage associated with infe-

rior alveolar nerve blocks. JADA 1995;126:1160-5.

7. Krafft TC, Hickel R. Clinical investigation into the incidence of direct damage to the lingual nerve caused by local anesthesia. J Craniofac Surg 1994;22(5):294-6.

8. Paxton MC, Hadley JN, Hadley MN, Edwards RC, Harrison SJ. Chorda tympani nerve injury following inferior alveolar injection: a review of two cases. JADA 1994;125:1003-6.

9. Ehrenfeld M, Cornelius CP, Altenmuller E, Riediger D, Sahl W. Nerve injuries following nerve blocking in the pterygomandibular space. Dtsch Zahnarztl Z 1992;47:36-9.

10. Harn SD, Durham TM. Incidence of lingual nerve trauma and postinjection complications in conventional mandibular block anesthesia. JADA 1990;121:519-23.

11. Pogrel MA, Schmidt BL. Trigeminal nerve chemical neurotrauma from injectable materials. Oral Maxillofac Surg Clin N Am 2001;13:247-54.

12. Malamed SF. Handbook of local anesthesia. 3rd ed. St. Louis: Mosby-Year Book; 1990:203-4.

13. Allen GD. Dental anesthesia and analgesia. 3rd ed. Baltimore: Williams & Wilkins; 1984:167.